



Patient

NHS No

D.O.B.

Patient Ref

Reason

Graft synthetic fem-pop

Outcome

Occlusion, Calcified, Poor Images, Oedema

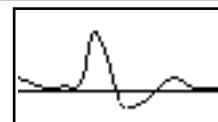
## Right

## Left

Brachial

Common Femoral

Good



High Thigh

Low Thigh

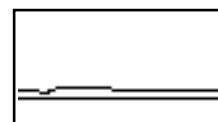
Popliteal

High Calf

Peroneal

Anterior Tibial

Weak/Absent



Posterior Tibial

Dorsalis Pedis

Toe Pressure

Post Exercise

## Notes

LEFT LOWER LIMB ARTERIAL DUPLEX - SYNTHETIC FEM-POP BYPASS SURVEILLANCE.

CFA has mild disease 81cm/s triphasic.

The graft appears to be occluded throughout its length with anechoic material ?soft plaque ?thrombus.

Distal anastomosis not visualised.

No colour-flow noted in the popliteal artery and TPT ?patency.

ATA some poor, weak, venous-like monophasic flow noted at the ankle, PSV 9cm/s.

PTA is too heavily calcified to determine patency.

Assessed by

Lukasz Koprowski

Checked by



Patient

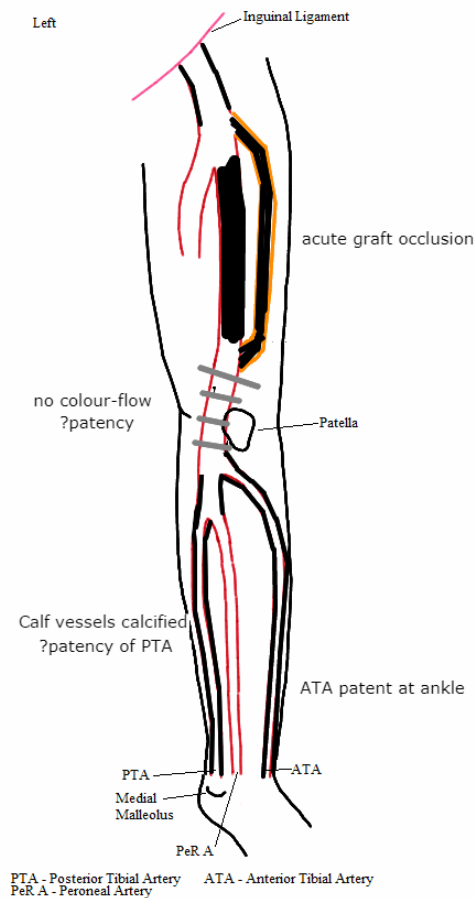
NHS No

D.O.B.

Patient Ref

Pressure not assessed at this time due to patients pain and feeling very unwell.

INCIDENTAL FINDING: a mixed echogenic, avascular mass noted in the left groin, measuring ~1.8 cm ML x ~1.1cm TS ?lymph node.



Assessed by

Lukasz Koprowski

Checked by